



Effective Dose of Herbal Gold Nanoparticles for Protection of Acetaminophen-Induced Hepatotoxicity in Male Albino Rats

Mousumi Mitra¹ · Amit Bandyopadhyay² · Gouriprasad Datta³ · Dilip K Nandi¹

© Springer Science+Business Media, LLC, part of Springer Nature 2020

Abstract

Overdose of acetaminophen causes hepatotoxicity due to NAPQI formation. The green synthesis of gold nanoparticles represents as a novel drug carrier in the field of drug delivery system. This study was designed to investigate the protective effect of green synthesized herbal gold nanoparticles (AuNPs) using the aqueous bark extract of *Terminalia arjuna* against acetaminophen-induced hepatotoxicity in an experimental rat model. In this study, group 1 served as normal control; group 2 received acetaminophen intraperitoneally at a concentration of 500 mg/kg of body weight for 14 days; and groups 3, 4, 5, and 6 were co-administered with acetaminophen (500 mg/kg/day) and AuNPs (55, 175, 550, 2000 µg/kg/day) intraperitoneally for 14 days. After 14 days, all animals were sacrificed for biochemical and histopathological studies. Among different experimental doses of AuNPs (55, 175, 550, 2000 µg/kg/day), dose 175 µg/kg/day showed more potent activity towards wellness parameters, biochemical indices, and histopathological studies. There was a significant ($p < 0.05$) increase in SGOT, SGPT, ALP, bilirubin, and MDA levels, but a significant decrease in SOD, CAT, and GSH activities in the hepatotoxic group in comparison with the control group, but co-administration with AuNPs (175 µg/kg/day) restored the activities of these biochemical markers. Hence, this study confirmed that AuNPs at a dose 175 µg/kg/day has better hepatoprotective efficacy.

Keywords Acetaminophen · AuNPs · *Terminalia arjuna* · Hepatotoxicity

1 Introduction

Acetaminophen, also known as paracetamol (*N*-acetyl *p*-amino phenol; APAP), is a widely used safe drug when prescribed in therapeutic doses for a wide range of treatments [1]. Acetaminophen is one of the most widely used analgesic/antipyretic agents in the world because of its overall efficacy and safety. A serious complication caused by acetaminophen is hepatotoxicity due to *N*-acetyl-*p*-benzoquinone imine (NAPQI) formation observed after large overdoses of the drug [2]. The liver mainly detoxifies toxic chemicals and drugs and becomes the main target organ for all xenobiotics.

Hepatotoxicity is one of the major endangerment to health in the present society. Herbs and herbal products are traditionally used for protecting liver function. Medicinal herbs together with metals and minerals are very useful in the treatment and management of pathophysiological conditions [3] due to their nanometer size range [4] and they are very powerful and do not react with the tissues in the body [5]. Mainly, there are three pathways for acetaminophen metabolism: conjugation with sulfate, phenolic glucuronide, and metabolism by the cytochrome P450 oxidase enzyme system [6, 7]. Through sulfation and glucuronidation pathways, 90% of the ingested dose gets metabolized and the remaining 5% of the dose is metabolized through the cytochrome P450 oxidase enzyme system [8]. Metabolism of cytochrome P450 oxidase produces a metabolite, NAPQI, which causes hepatic and renal toxicity [9, 10]. In overdoses of acetaminophen, the glucuronidation and sulfation pathways become saturated, and the rate of NAPQI formation increases. Then, as a result, body's reduced glutathione stores get depleted and NAPQI gets covalently bound to cells, causing necrosis, resulting in hepato-renal dysfunction [11]. Indeed, several research works are going on throughout for the search of protective biomolecules that would be effective in protecting the liver, kidney,

✉ Dilip K Nandi
dilipnandi2004@yahoo.co.in

¹ Department of Human Physiology, Raja Narendra Lal Khan Women's College (Autonomous), Midnapore, West Bengal 721102, India

² Department of Physiology, University of Calcutta, Kolkata, West Bengal 700009, India

³ Department of Physiology, Rammohan College, 102/1, Raja Rammohan Sarani, Kolkata, West Bengal 700009, India

and other organs from the deleterious effects of acetaminophen overdose [12, 13]. The liver exhibits a potent role in the metabolism of xenobiotics by regulating the synthesis, secretion, and metabolism of xenobiotics. Various physiochemical functions of the body, such as oxidation, reduction, hydrolysis, hydroxylation, sulfation, conjugation, and acetylation, are controlled by the liver itself. Hepatic damage is associated with distortion of different metabolic functions of the liver [14].

Nanomedicine can be defined as the science that uses nanotechnology to supervise, maintain, treat, and prevent diseases and control the human biological system at a nanoscale range, using nanostructures and nanodevices. It has a huge potential in bringing benefits in research areas and its application [15]. Among the metallic nanoparticles, especially, green synthesized gold nanoparticles represent as a novel drug carrier in the field of drug delivery system. The green synthesis of nanoparticles using plants provides improvement over other methods as it is simple, cost effective, safe, environmentally friendly, and relatively reproducible [16]. Metal nanoparticles are synthesized using the reducing property of herbs with effective therapeutic potential. In this present study, the herbal gold nanoparticles were synthesized using the reducing property of *Terminalia arjuna* bark extract. *Terminalia arjuna* is an important medicinal herb that belongs to the Combretaceae family. Various bioactive components such as triterpenoid, tannin, saponin, gallic acid, ellagic acid, and proanthocyanidines are present in *Terminalia arjuna* bark extract [17]. The bark of this tree has been widely used in the preparation of Ayurvedic formulations with powerful cardiotoxic [18], antioxidative [19], antiuremic, and antimicrobial [20] properties.

Hence, this present study aims to investigate hepatoprotective as well as antioxidant property of green synthesized herbal gold nanoparticles (AuNPs) using an aqueous bark extract of *Terminalia arjuna* against acetaminophen-induced hepatotoxicity in experimental rats by determining their wellness parameters, biochemical indices, and through histopathological studies.

2 Methods

2.1 Green Synthesis and Characterization of Herbal Gold Nanoparticles Using Aqueous Bark Extract of *Terminalia arjuna*

Herbal gold nanoparticles were synthesized and characterized according to Mitra et al. [21]. *Terminalia arjuna* bark was collected from the laterite region of the Gope Palace (Raja Narendra Lal Khan Women's College), Paschim Medinipur district, Midnapore, West Bengal, India, and the plant voucher number is RNLKWC/121/2016. The collected bark samples were washed, air-dried, and then ground into fine powder. In

100 mL of distilled water, 1 g of bark powder was dissolved and then incubated for 15 min at 50–60 °C. Then, the filtrate was collected by using Whatman no. 1 filter papers. Then, 10 mL of aliquot was added to 100 mL of 1 mM HAuCl₄ solution and the reaction was stirred for 10 min at 60–70 °C. The change in the color from pale yellow to ruby red indicated the formation of green synthesized herbal gold nanoparticles (AuNPs). This indicated *Terminalia arjuna*-mediated transformation of chloroauric acid in green synthesized AuNPs. The green synthesized AuNPs were characterized by visual observations, UV-Visible spectral analysis, FESEM and HRTEM with EDX, FTIR, XRD, and DLS analyses.

2.2 Experimental Animals

The experimental study was conducted on 36 male Wistar albino rats weighing 100 to 120 g, obtained from authorized Chakraborty animal suppliers, Kolkata (M/S Chakraborty Enterprise, registration no.: 1443/PO/b/11/CPCSEA). The animals were housed in polypropylene cages. They were kept under standard laboratory condition that includes 22 ± 4 °C, 12-h light/dark cycle, and 50 ± 10% humidity with proper supplementation of standard food and water ad libitum. The animals were acclimated to this environmental condition for 7 days before treatment.

All animal experiments were performed as per the Animal Ethical Committee guidelines of Raja Narendra Lal Khan Women's College (reference number: 14/IAEC (05)/RNLKWC/2019) and were maintained as per Committee for the Purpose of Control and Supervision of Experiments on Animal (CPCSEA), Government of India (registration no.: 1905/PO/Re/S/2016/CPCSEA). All experimental protocols have been approved by the Constitution of Institutional Animal Ethics Committee (IAEC) of Raja Narendra Lal Khan Women's College (Autonomous), Midnapore, 721102, West Bengal, India, registered under CPCSEA.

2.3 Experimental Design

The dose-response study of AuNPs against acetaminophen-induced hepatotoxicity in rats was conducted as per Organisation for Economic Co-operation and Development (OECD) guidelines 425 [22].

The rats were divided into six groups (6 rats in each group). Group 1 served as control, group 2 animals were treated with acetaminophen (paracetamol) intraperitoneally at a concentration of 500 mg/kg of body weight for 14 days. Group 3 animals were co-administered with AuNPs (55 µg/kg/day) and acetaminophen (500 mg/kg/day) intraperitoneally for 14 days. Group 4 animals were co-administered with AuNPs (175 µg/kg/day) along with acetaminophen. Group 5 animals received intraperitoneal infusion of acetaminophen along with co-administration of AuNPs (550 µg/kg/day) for 14 days.

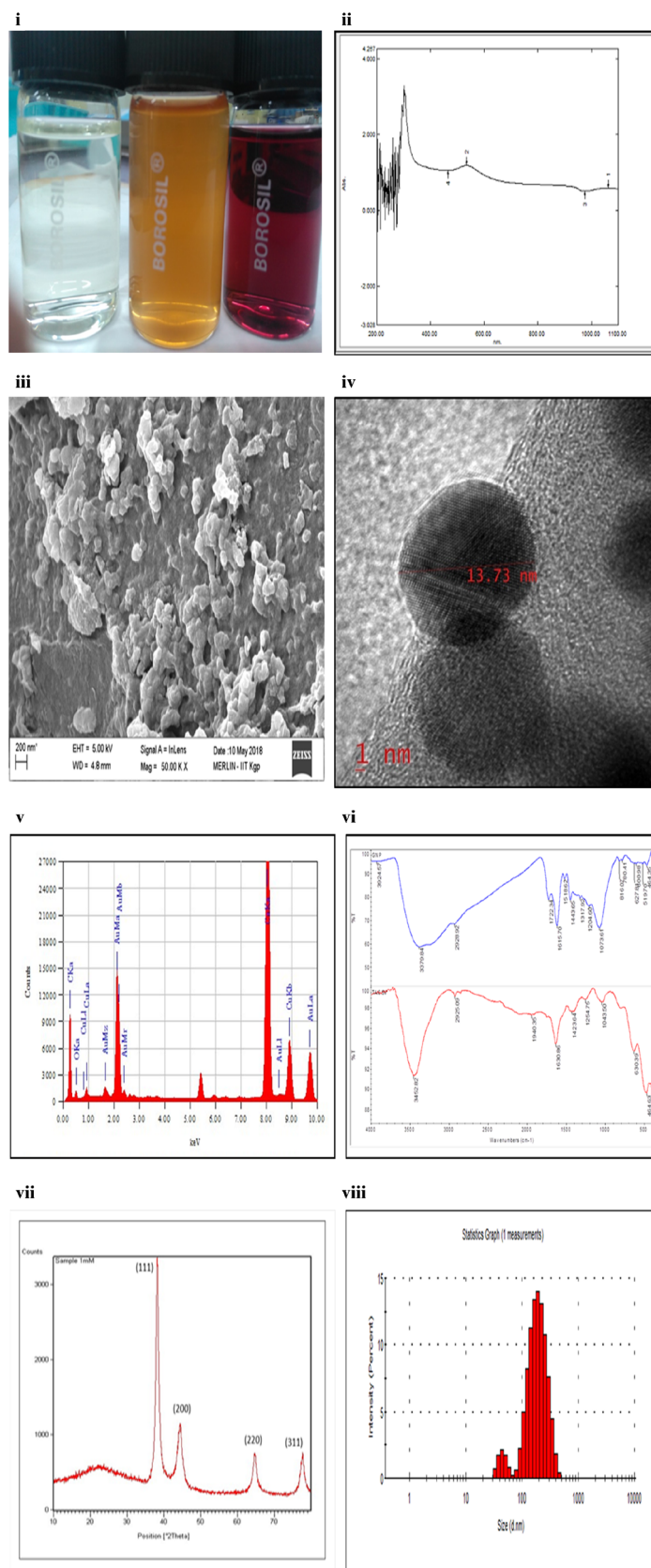


Fig. 1 Characterization of herbal gold nanoparticles. (i) Color change during phyto-reduction of chloroauric acid to ruby red color, (ii) UV spectra of AuNPs, (iii) FESEM image of AuNPs, (iv) HRTEM image

of AuNPs, (v) EDX spectroscopy of AuNPs, (vi) FTIR study of AuNPs (blue) and *Terminalia arjuna* bark extract (red), (vii) XRD study of AuNPs, (viii) DLS study of AuNPs

Table 1 Effects of different doses of AuNPs on body weight of acetaminophen-induced hepatotoxicity in male rats

Groups	Initial body weight (g), mean \pm SE	Final body weight (g), mean \pm SE	Elevation/diminution in body growth (g%)
1	149.16 \pm 2.08	153 \pm 1.82	3.84 \uparrow
2	150 \pm 1.59*	149 \pm 0.81*	1 \downarrow
3	146 \pm 2.90*	151.66 \pm 2.59*	5.66 \uparrow
4	145.83 \pm 1.53*	152.33 \pm 1.60*	6.5 \uparrow
5	148 \pm 2.73*	152.16 \pm 1.70*	4.16 \uparrow
6	148.83 \pm 1.74*	151.33 \pm 1.33*	2.5 \uparrow

Data are expressed as mean \pm SE of mean ($n = 6$). ANOVA followed by multiple two-tailed t tests and data with superscripts (*) in a specific vertical column indicate no significant difference ($p < 0.05$) compared with the control group.

Group 6 animals were co-administered with AuNPs (2000 $\mu\text{g}/\text{kg}/\text{day}$) as well as acetaminophen for 14 days. In another separate group, five animals were taken ($n = 5$) to study for the limit dose test of AuNPs. The animals received AuNPs (5000 $\mu\text{g}/\text{kg}/\text{day}$) intraperitoneally for 2 days.

For the experimental study, AuNPs and acetaminophen were administered in the mid-morning at an interval of 24 h after the supplementation of a normal diet.

2.4 Clinical Observation

During the wellness parameter study, observations were done at least twice daily for signs and symptoms of toxicity. Effects of treatment on the general health of animal's body weight, skin and fur, eyes, mucus membrane, tremor, convulsions, salivations, diarrhea, lethargy, sleep, and mortality were recorded.

2.5 Animal Sacrifice

After 14 days, the animals were sacrificed and blood was collected from the aorta after which liver tissue was gently removed and weighed. The collected tissue was first perfused

Table 2 Comparison of mean weight of liver between groups 1, 2, 3, 4, 5, and 6

Groups	Weight of liver (g) (mean \pm SE)
1	5.05 \pm 0.13
2	3.72 \pm 0.19*
3	5.00 \pm 0.13
4	5.01 \pm 0.09
5	4.94 \pm 0.10
6	3.88 \pm 0.10 [#]

Data are expressed as mean \pm SE of mean ($n = 6$). ANOVA followed by multiple two-tailed t tests and data with different superscripts (*, #) in a specific vertical column indicate significant difference ($p < 0.05$) compared with the control group

with phosphate-buffered saline (PBS) and then half of the tissue was stored at $-20\text{ }^\circ\text{C}$ in a sterile container for preparation of tissue homogenates. The other remaining half of the tissue was preserved in 10% neutral formaldehyde solution until processed for histopathological analysis.

2.6 Separation of Serum and Homogenization of Liver Tissue

The blood samples were centrifuged at $1500\times g$ for 10 min and serum was separated. The isolated serum samples were kept on $-20\text{ }^\circ\text{C}$ for different biochemical analyses. The collected liver tissue was homogenized in ice-cold PBS, pH = 7.4. The homogenates were centrifuged at $1000\times g$ for 5 min at $4\text{ }^\circ\text{C}$ and the resulting supernatant was stored at $-20\text{ }^\circ\text{C}$ for different biochemical estimations.

2.7 Biochemical Parameters

2.7.1 Determination of Different Hepatic Markers

Serum hepatic marker enzymes such as serum glutamate oxaloacetate transaminase (SGOT) [23], serum glutamate pyruvate transaminase (SGPT) [24], alkaline phosphatase (ALP) [25], and bilirubin [26] were measured by using the Agappe diagnostic kit. These markers will help to evaluate the extent of liver toxicity.

2.7.2 Oxidative Stress Profile

Lipid peroxidation in liver tissue homogenate was determined in terms of thiobarbituric acid-reactive substance (TBARS) formation [27]. The tissue homogenate was mixed with 20% TCA (1.5 mL) and 1.34% TBA (1.5 mL) and heated for 30 min at $100\text{ }^\circ\text{C}$. After cooling, the sample was centrifuged for 5 min in $2000\times g$. Then, the optical density of the supernatant was measured at 535 nm. TBARS as malondialdehyde (MDA) concentrations were calculated by

Table 3 Observation of different wellness parameters of rats for the limit test of green synthesized herbal gold nanoparticles (AuNPs) using bark extract of *Terminalia arjuna* at the dosage rate of 2000 µg/kg/day

Parameters	Observation time																						
	30 min		2 h		4 h		6 h		8 h		10 h		12 h		18 h		24 h		36 h		48 h		
	C	E	C	E	C	E	C	E	C	E	C	E	C	E	C	E	C	E	C	E	C	E	
Skin fur	N	N	N	N	N	N	N	N	N	N	N	N	N	N	N	N	N	N	N	N	N	N	N
Eyes	N	N	N	N	N	N	N	N	N	N	N	N	N	N	N	N	N	N	N	N	N	N	R
Mucus membrane	N	N	N	N	N	N	N	N	N	N	N	N	N	N	N	N	N	N	N	N	N	N	N
Salivation	X	X	X	X	X	X	X	X	X	X	X	X	X	X	X	X	X	X	X	Y	X	X	Y
Lethargy	X	X	X	X	X	X	X	X	X	X	X	X	X	X	X	X	X	X	X	X	X	X	X
Sleep	N	N	N	N	N	N	N	N	N	N	N	N	N	N	N	N	N	N	N	N	N	N	N
Convulsions	X	X	X	X	X	X	X	X	X	X	X	X	X	X	X	X	X	X	X	X	X	X	X
Tremor	X	X	X	X	X	X	X	X	X	X	X	X	X	X	X	X	X	X	X	X	X	X	X
Diarrhea	X	X	X	X	X	X	X	X	X	X	X	X	X	X	X	X	X	X	X	X	X	X	X
Morbidity	X	X	X	X	X	X	X	X	X	X	X	X	X	X	X	X	X	X	X	X	X	X	X
Mortality	X	X	X	X	X	X	X	X	X	X	X	X	X	X	X	X	X	X	X	X	X	X	X

C control, E experimental, R red, N normal, X no, Y yes

using the molar extinction coefficient $1.56 \times 10^5 \text{ M}^{-1} \text{ cm}^{-1}$ and expressed as nanomoles of MDA formed/milligrams of protein.

2.7.3 Antioxidant Enzyme Profile

Superoxide dismutase (SOD) activity of the liver tissue homogenate was determined by its ability to inhibit auto-oxidation of pyrogallol [28]. The samples were measured at 420 nm at 25 °C for 3 min. SOD activity was expressed as unit/milligrams of protein.

Catalase (CAT) activity of these tissue homogenates was measured by the method of Luck [29]. Catalase activity was calculated by using a molar extinction coefficient of $43.6 \text{ M}^{-1} \text{ cm}^{-1}$ for H₂O₂. The level of CAT was expressed as unit/milligrams.

2.7.4 Determination of Reduced Glutathione Level

The glutathione (GSH) level in the liver tissue homogenate was estimated according to Moron et al. [30]. The liver sample was mixed with 25% of TCA, and then it was centrifuged at

Table 4 Observation of different wellness parameters of rats for the limit test of green synthesized herbal gold nanoparticles (AuNPs) using bark extract of *Terminalia arjuna* at the dosage rate of 5000 µg/kg/day

Parameters	Observation time																					
	30 min		2 h		4 h		6 h		8 h		10 h		12 h		18 h		24 h		36 h		48 h	
	C	E	C	E	C	E	C	E	C	E	C	E	C	E	C	E	C	E	C	E	C	E
Skin fur	N	N	N	N	N	N	N	N	N	N	N	N	N	FL	N	FL	N	1D4L	N	2D3L	N	3D2L
Eyes	N	N	N	N	N	N	N	R	N	R	N	R	N	R	N	R	N	1D4L	N	2D3L	N	3D2L
Mucus membrane	N	N	N	N	N	N	N	A	N	A	N	A	N	A	N	A	N	1D4L	N	2D3L	N	3D2L
Salivation	X	X	X	X	X	Y	X	Y	X	Y	X	Y	X	Y	X	Y	X	1D4L	X	2D3L	X	4D1L
Lethargy	X	X	X	X	X	Y	X	Y	X	Y	X	Y	X	Y	X	Y	X	1D4L	X	2D3L	X	4D1L
Sleep	N	N	N	N	N	N	N	N	N	N	N	N	N	A	N	A	N	1D4L	N	2D3L	N	4D1L
Convulsions	X	X	X	X	X	Y	X	Y	X	Y	X	Y	X	Y	X	Y	X	1D4L	X	2D3L	X	4D1L
Tremor	X	X	X	X	X	X	X	Y	X	Y	X	Y	X	Y	X	Y	X	1D4L	X	2D3L	X	4D1L
Diarrhea	X	X	X	X	X	X	X	X	X	X	X	X	X	X	X	X	X	1D4L	X	2D3L	X	4D1L
Morbidity	X	X	X	X	X	Y	X	Y	X	Y	X	Y	X	Y	X	Y	X	1D4L	X	2D3L	X	4D1L
Mortality	X	X	X	X	X	X	X	X	X	X	X	X	X	X	X	X	X	1D4L	X	2D3L	X	4D1L

A affected, C control, D dead, E experimental, FL fur loss, L live, N normal, R red, X no, Y yes

2000×g for 15 min. Then, 1 mL of 0.2 M sodium phosphate buffer was added to the supernatant. Later, 2 mL of 0.6 mM DTNB (Ellman's reagent) was added to it. The optical density of the yellow-colored complex formed by the reaction of GSH and DTNB was measured after 10 min at 405 nm.

2.8 Histopathological Assessment

The histopathological analysis of liver tissue for each experimental group was performed by the method of Iranloye and Bolarinwa [31]. The collected liver tissue was fixed in 10% formalin solution and then dehydrated in ascending grade alcohol (70–100%) followed by clearing in xylene. Then, paraffin embedding was done at 58 °C for 4 to 5 h, followed by paraffin block preparation. Afterwards, thick sections (5–6 μm) were prepared using a rotary microtome. Then, the sections were deparaffinized with xylene, stained with hematoxylin-eosin, and followed by mounting with DPX with a coverslip. Prepared slides were observed for histopathological alterations under a microscope (× 400).

2.9 Statistical Analysis

The collected data were statistically calculated by using the statistical package Origin 6.1 (Northampton, MA, USA). The data were expressed as the mean ± SE of mean, $n = 6$. A comparison was done between the means of control and with all experimental groups, by ANOVA followed by multiple two-tailed t tests. Bars for a specific data differ from each other significantly at the level of $p < 0.05$.

3 Results and Discussion

The current investigation focuses on the effective role of green synthesized gold nanoparticles against acetaminophen-induced hepatotoxicity in male Wistar rats. The AuNPs were synthesized using *Terminalia arjuna* bark extract, which acted as both reducing and capping agents. This greener herbal method approach is eco-friendly, cost effective, and rapid and also can be easily scaled up for large-scale syntheses. In visual observation, the change in color from pale yellow to ruby red was noted due to the reduction of gold ions which indicated the formation of green synthesized AuNPs (Fig. 1(i)). In UV-Visible spectral analysis, the SPR band centered at 524 nm (Fig. 1(ii)). When the SPR bands centered between 500 and 600 nm, it confirms the formation of green synthesized AuNPs in the solution. FESEM and HRTEM analyses confirmed the spherical shape of the nanoparticles having sizes between 7 and 20 nm (Fig. 1(iii, iv)). EDX spectroscopy confirmed the distribution of elemental gold in green synthesized

Fig. 2 a, b Effects of different doses of AuNPs on serum biochemical parameters SGOT and SGPT in rats after intraperitoneal administration of acetaminophen. Data are expressed as mean ± SE of mean ($n = 6$). ANOVA followed by multiple two-tailed t tests and data with different superscripts (*, **, #, ##, ***) in a specific vertical column indicate significant difference ($p < 0.05$) compared with the control group. **c, d** Effects of different doses of AuNPs on serum ALP and total bilirubin in rats after intraperitoneal administration of acetaminophen. Data are expressed as mean ± SE of mean ($n = 6$). ANOVA followed by multiple two-tailed t tests and data with different superscripts (*, **, #, ##, ***) in a specific vertical column indicate significant difference ($p < 0.05$) compared with the control group. **e, f** Effects of different doses of AuNPs on serum direct bilirubin and MDA content in rats after intraperitoneal administration of acetaminophen. Data are expressed as mean ± SE of mean ($n = 6$). ANOVA followed by multiple two-tailed t tests and data with different superscripts (*, **, #, ##, ***) in a specific vertical column indicate significant difference ($p < 0.05$) compared with the control group. **g–i** Effects of different doses of AuNPs on SOD, catalase, and GSH levels in rats after intraperitoneal administration of acetaminophen. Data are expressed as mean ± SE of mean ($n = 6$). ANOVA followed by multiple two-tailed t tests and data with different superscripts (*, **, #, ##, ***) in a specific vertical column indicate significant difference ($p < 0.05$) compared with the control group. Groups: group 1, control; group 2, acetaminophen (500 mg/kg/day) treated; group 3, acetaminophen + AuNPs (55 μg/kg/day); group 4, acetaminophen + AuNPs (175 μg/kg/day); group 5, acetaminophen + AuNPs (550 μg/kg/day); group 6, acetaminophen + AuNPs (2000 μg/kg/day)

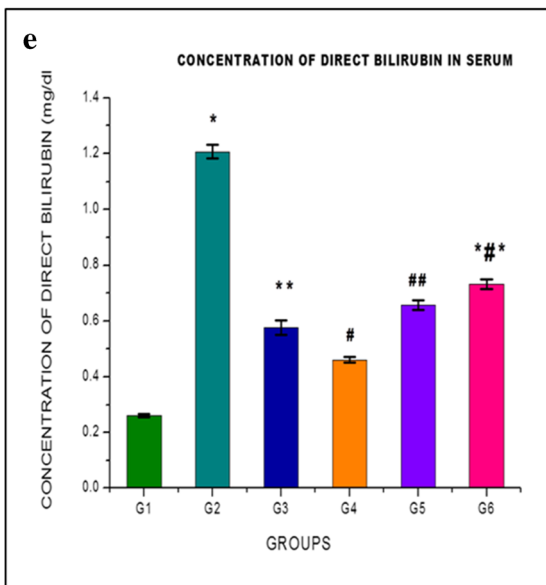
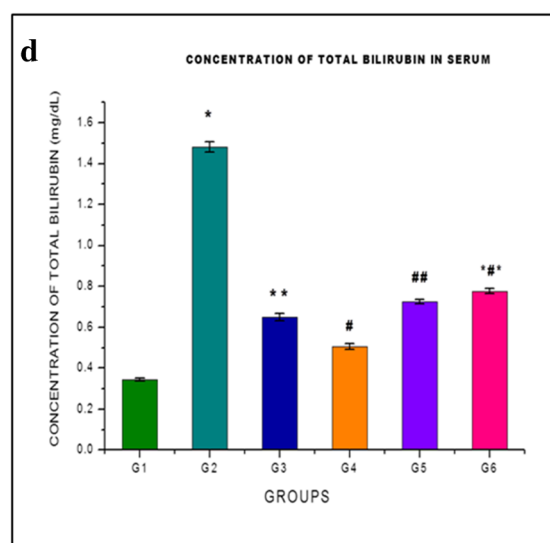
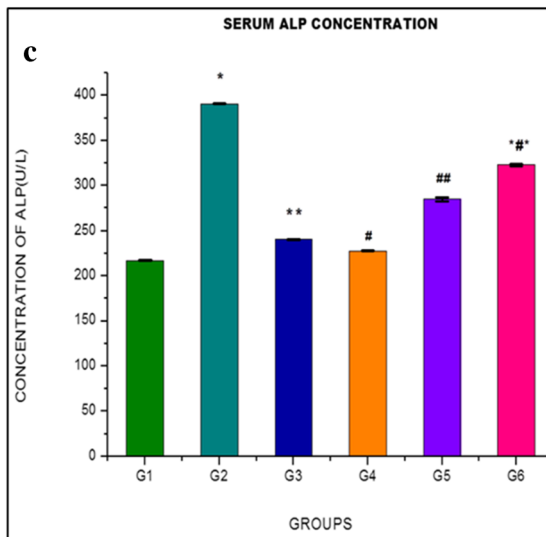
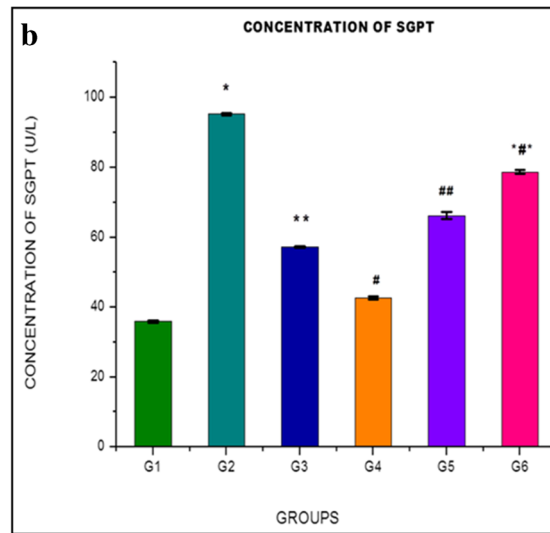
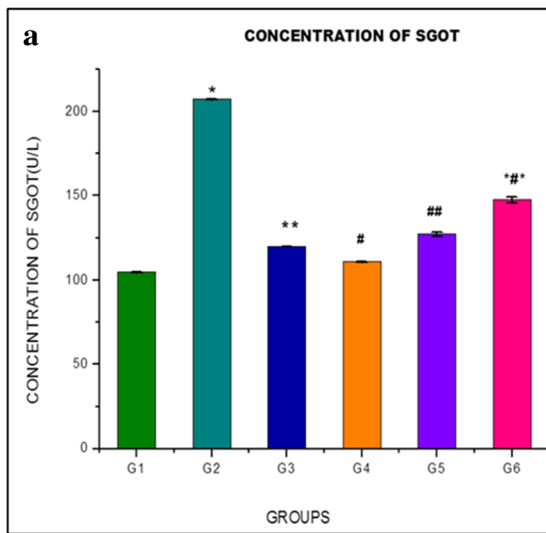
AuNPs (Fig. 1(v)). An FTIR study predicted the potential biomolecules responsible for the reduction of Au³⁺ ions and capping of reduced Au⁰ NPs synthesized using *Terminalia arjuna* bark extract (Fig. 1(vi)). XRD analysis showed the crystalline nature of the synthesized nanoparticles (Fig. 1(vii)). In the DLS study, the measured size of the green synthesized AuNPs ranged between 7 and 90 nm (Fig. 1(viii)). The nanoparticles have a larger hydrodynamic diameter due to the hydrated state of the sample in the DLS method [21].

3.1 Body Weight of Rats

Rats were first initially weighed before the experiment and were weighed again towards the end of the experiment. The initial mean weight of rats was 149.16 ± 2.08, 150 ± 1.59, 146 ± 2.90, 145.83 ± 1.53, 148 ± 2.73, and 148.83 ± 1.74 g in groups 1, 2, 3, 4, 5, and 6 respectively. The final mean body weight of the rats was 158.66 ± 1.25, 150.33 ± 1.33, 155.66 ± 3.25, 157.5 ± 1.97, 156 ± 1.94, and 152 ± 1.77 g in groups 1, 2, 3, 4, 5, and 6 respectively. The mean weight of rats was not significantly different ($p < 0.05$) when compared between groups 1, 2, 3, 4, 5, and 6 respectively (Table 1).

3.2 Gross Examination of the Liver

The mean weight of the liver was 5.05 ± 0.13, 3.72 ± 0.19, 5.00 ± 0.13, 5.01 ± 0.09, 4.94 ± 0.10, and 3.88 ± 0.10 g in groups 1, 2, 3, 4, 5, and 6 respectively. In acetaminophen-



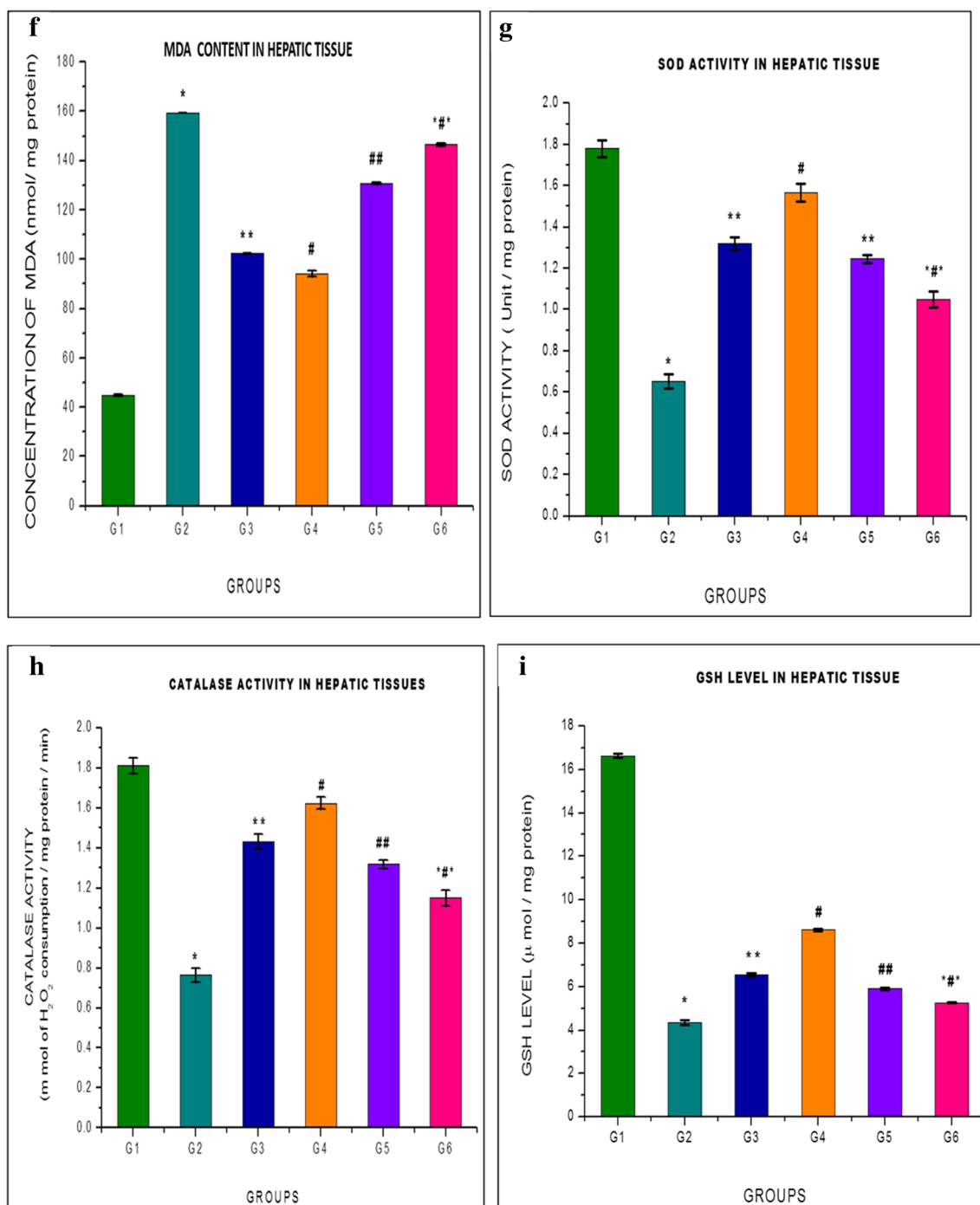


Fig. 2 (continued)

treated group 2 rats, there was a significant ($p < 0.05$) decrease in the liver weight when compared with the control group. Co-administration of AuNPs at dose 175 $\mu\text{g}/\text{kg}/\text{day}$ significantly ($p < 0.05$) increased the weight of liver with respect to group 2 rats. Gross examination of the liver specimen showed that it was reddish brown in color with firm consistency, in all the rats of groups 1, 2, 3, 4, 5, and 6 respectively (Table 2).

3.3 Wellness Parameter Study

The wellness study was conducted to ascertain the behavioral changes and mortality rate of the experimental animals in acute exposure of AuNPs at the limit dose of 2000 $\mu\text{g}/\text{kg}$ body weight and 5000 $\mu\text{g}/\text{kg}$ body weight. During the study, a first limit test of AuNPs at a dose 2000 $\mu\text{g}/\text{kg}$ body weight was

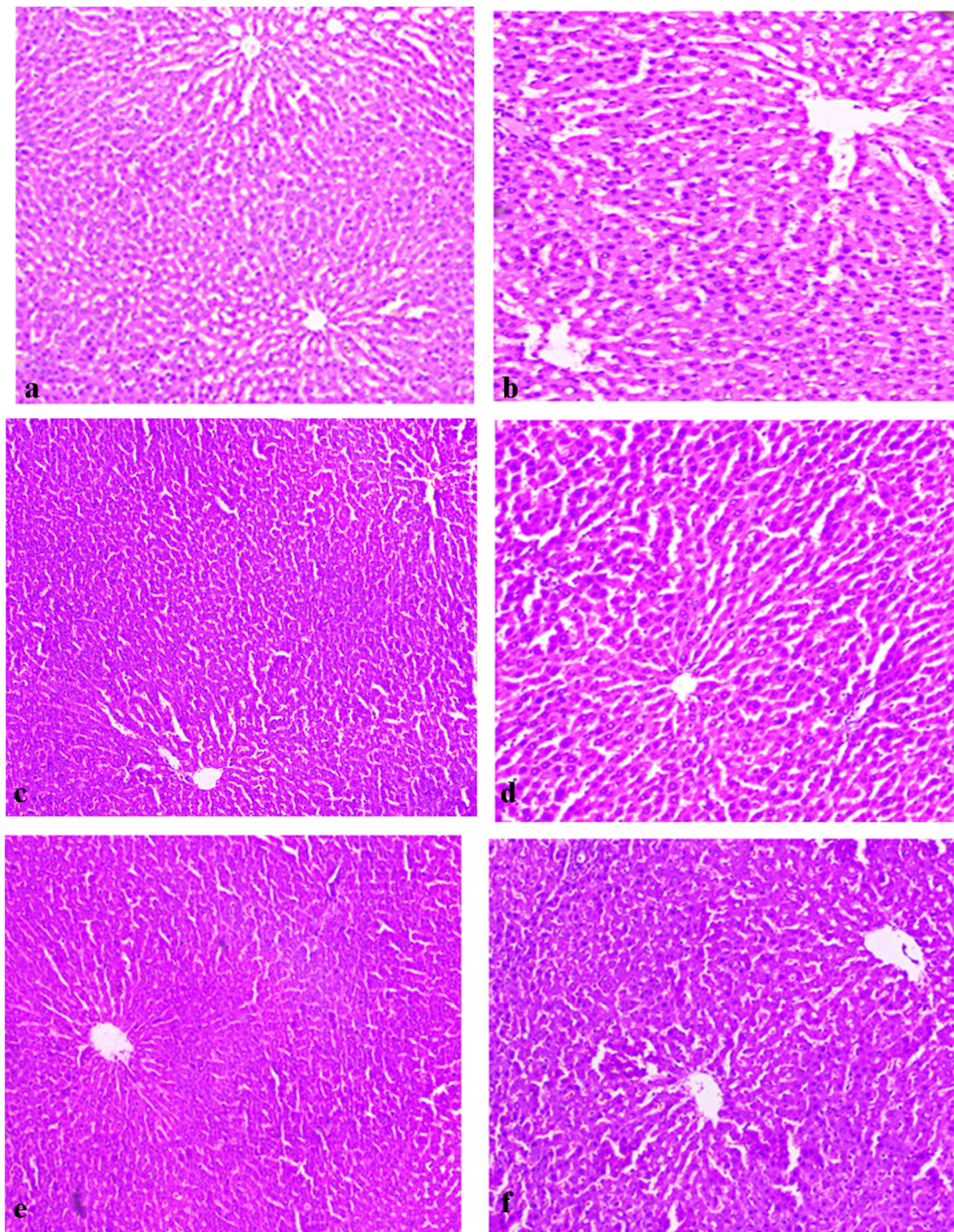


Fig. 3 Histopathological analysis of liver tissue. **a** Normal histological structure of liver tissue like normal central vein, normal hepatocytes with proper nuclei of the control group (group 1) rats. **b** Acetaminophen-treated group (group 2) showing severe cellular disruptions as damaged hepatocytes, enlarged central vein, and cellular necrosis. **d** Co-administration of AuNPs (175 $\mu\text{g}/\text{kg}/\text{day}$) along with the acetaminophen treatment group (group 4) showing well-organized and repaired hepatic cells with proper nuclei and normally repaired central vein similar to the

control group rats (group 1). **c, e, f** Co-administration of AuNPs at various doses (55, 550, 2000 $\mu\text{g}/\text{kg}/\text{day}$) along with the acetaminophen-treated groups (groups 3, 5, and 6) represented slightly repaired hepatic cells and slightly enlarged central vein. Group 1, control; group 2, acetaminophen treated; group 3, acetaminophen + AuNPs (55 $\mu\text{g}/\text{kg}/\text{day}$); group 4, acetaminophen + AuNPs (175 $\mu\text{g}/\text{kg}/\text{day}$); group 5, acetaminophen + AuNPs (550 $\mu\text{g}/\text{kg}/\text{day}$); group 6, acetaminophen + AuNPs (2000 $\mu\text{g}/\text{kg}/\text{day}$)

done, but it was noted that with duration of time interval, all experimental animals well survived (Table 3), so a limit dose

test was further conducted at a dose 5000 $\mu\text{g}/\text{kg}$ body weight according to OECD guidelines 425. It has been observed that

after 2 h of administration of AuNPs at a dose 5000 $\mu\text{g}/\text{kg}$ body weight, salivation and convulsion started and lethargy thrived in some experimental animals during a 4-h interval. It was observed that eye color became extensively red, the mucus membrane was affected, and tremor occurred in experimental animals by 6 h. The animals began to lose their skin and fur, and sleep was affected in 12 h from the administration of the said dose. After 24 h, one experimental animal died and other animals were associated with increased morbidity. After 36 h, two animals were dead and within 48 h of time interval, four were dead and one was alive associated with morbidity (Table 4). Hence, the approximate LD50 of AuNPs is less than 5000 $\mu\text{g}/\text{kg}$ body weight.

3.4 Estimation of SGOT, SGPT, and ALP

Aminotransferases (SGOT, SGPT) and alkaline phosphatase (ALP) are the most sensitive and widely used hepatobiliary enzymes present normally in the liver. These enzymes are reasonably sensitive indicators of liver damage with potential liver toxicity. In this study, effects of different doses of AuNPs on SGOT, SGPT, and ALP levels were observed (Fig. 2a–c). Liver enzymes significantly ($p < 0.05$) increased in group 2 acetaminophen (500 mg/kg/day)-treated rats for 14 days in comparison with control group 1. The elevated levels of SGOT, SGPT, and ALP are sensitive indicators of cellular leakage and loss of functional integrity of the hepatic cell membranes implying hepatocellular damage [32]. The rise in SGOT is usually accompanied by an increase in the SGPT level, which helps in the conversion of amino acids to keto acids [33]. The increase in serum ALP level is due to the increased synthesis in the presence of increasing biliary pressure. However, co-administration of AuNPs at a dose 175

Table 5 Scoring of histopathological examination in liver tissue of different experimental groups. The 6-point scale for fibrosis stage was applied for scoring liver toxicity: (0) indicates normal liver, (1) indicates mild toxicity, (2) indicates moderate toxicity, (3) indicates severe toxicity, (4) indicates modest severe toxicity, (5) indicates extremely severe toxicity, (6) indicates extremely severe toxicity and damage. Group 1, control; group 2, acetaminophen treated; group 3, acetaminophen + AuNPs (55 $\mu\text{g}/\text{kg}/\text{day}$); group 4, acetaminophen + AuNPs (175 $\mu\text{g}/\text{kg}/\text{day}$); group 5, acetaminophen + AuNPs (550 $\mu\text{g}/\text{kg}/\text{day}$); group 6, acetaminophen + AuNPs (2000 $\mu\text{g}/\text{kg}/\text{day}$)

Parameters	Group 1	Group 2	Group 3	Group 4	Group 5	Group 6
Cellular necrosis	0	6	0	0	1	3
Hepatocyte degeneration	0	6	1	0	1	3
Portal inflammation	0	5	0	0	2	4
Lipid accumulation	0	4	1	1	1	2
Lipid infiltration	0	4	1	1	1	2

$\mu\text{g}/\text{kg}/\text{day}$ for 14 days in treated group 4 rats significantly ($p < 0.05$) decreased the levels of SGOT, SGPT, and ALP in comparison with acetaminophen-treated group 2 rats as well as in other AuNP-co-administered groups in treated group 3 rats at dose 55 $\mu\text{g}/\text{kg}/\text{day}$, 550 $\mu\text{g}/\text{kg}/\text{day}$ in group 5 rats, and 2000 $\mu\text{g}/\text{kg}/\text{day}$ in treated group 6 rats for 14 days respectively. Hence, co-administration of AuNPs in treated group 4 rats effectively recovered the levels of SGOT, SGPT, and ALP, respectively, offering maximum hepatic protection.

3.5 Estimation of Total and Direct Bilirubin

Bilirubin is another important hepatic marker to evaluate the liver function. In acetaminophen-treated group 2 rats, significant ($p < 0.05$) elevation of total and direct bilirubin levels was observed compared with the control group 1. The rise in bilirubin levels after acetaminophen administration may be due to hepatocyte damage and defects of hepatic uptake. After co-administration of AuNPs (175 $\mu\text{g}/\text{kg}/\text{day}$) in treated group 4 rats, total and direct bilirubin levels significantly ($p < 0.05$) reduced in comparison with groups 2, 3, 5, and 6 respectively (Fig. 2d, e). The serum bilirubin level in treated group 4 rats restored significantly, ameliorating the hepatic function.

3.6 Estimation of Oxidative Stress Marker

Lipid peroxidation is a ROS-mediated process by which polyunsaturated fatty acids undergo peroxidation, producing α,β -unsaturated aldehydes such as malondialdehyde (MDA). Administration of acetaminophen in group 2 rats significantly ($p < 0.05$) elevated the MDA level in liver tissue homogenate as compared with the control group. Lipid peroxidation is caused due to redox cycling of the quinone imine metabolite of acetaminophen; NAPQI has been proposed [34]. Reaction of NAPQI with the ferrous-oxy form of cytochrome P450 stimulates ROS generation and oxidative stress in hepatic cells. This enhanced lipid peroxidation finally triggered hepatic tissue damage. Supplementation of AuNPs in group 4 (175 $\mu\text{g}/\text{kg}/\text{day}$) experimental animals had shown significant ($p < 0.05$) reduction of MDA levels more than acetaminophen-treated group 2 rats as well as in other doses of AuNP-co-administered groups 3, 5, and 6 rats respectively (Fig. 2f). Hence, treatment with AuNPs at a dose 175 $\mu\text{g}/\text{kg}/\text{day}$ showed the highest protective activity by reducing the oxidative stress as well as MDA formation in comparison with other groups.

3.7 Estimation of Antioxidant Enzyme Profile

It has been reported that cellular antioxidative enzymes (SOD, CAT) exert supportive defense against ROS generation, such as superoxide radicals, hydrogen peroxide, and

hydroxyl radicals within the cell by scavenging the toxic molecules [35]. A marked significant ($p < 0.05$) decrease in antioxidant enzymes (SOD and CAT) was noted in liver tissue homogenate of acetaminophen-treated group 2 rats with respect to the control group. Catalase helps to decompose hydrogen peroxide and protects the tissue from hydroxyl radicals [36]. Therefore, a decrease in the activity of these enzymes may cause deleterious effects due to the deposition of hydrogen peroxide and superoxide radicals. However, significant ($p < 0.05$) enhancement of SOD and CAT activities was observed in the case of 14-day treatment with AuNPs in group 4 (175 $\mu\text{g}/\text{kg}/\text{day}$) experimental animals in comparison with acetaminophen-treated group 2 rats as well as in other doses of AuNP-co-administered groups 3, 5, and 6 rats, respectively, hence protecting the liver from acetaminophen intoxication (Fig. 2g, h).

3.8 Estimation of Reduced Glutathione Level

Reduced GSH is a tripeptide containing a free thiol group that is a major non-enzymatic antioxidant. GSH is capable of preventing damage to cellular components caused by ROS generation and preservation of membrane protein thiols and as a substrate for glutathione peroxidase [37]. Acetaminophen treatment in group 2 rats caused significant ($p < 0.05$) reduction of GSH levels in liver tissue homogenates compared with the control group. This may be due to inactivation of the antioxidative enzymes and GSH at the site of tissue damage and accumulation of superoxide radicals. Co-administration of AuNPs in group 4 (175 $\mu\text{g}/\text{kg}/\text{day}$) rats significantly ($p < 0.05$) increased the level of GSH compared with acetaminophen-treated group 2 rats as well as in other doses of AuNP-co-administered groups in groups 3, 5, and 6 rats respectively (Fig. 2i). Hence, AuNPs at a dose 175 $\mu\text{g}/\text{kg}/\text{day}$ helped in protecting the antioxidant machineries of the liver.

3.9 Histopathological Examinations

In this histopathological study, marked changes were observed in acetaminophen (500 $\text{mg}/\text{kg}/\text{day}$)-treated group 2 rats compared with the control group. Acetaminophen-mediated liver damage is due to enhanced rates of lipid peroxidation, which in turn increases production of malondialdehyde resulting in the degeneration of nuclei, accumulation of lipid, fatty degeneration, inflammatory responses, and necrosis of hepatocytes [38]. Histology of the liver tissue in the control group showed normal hepatocellular architecture along with prominent hepatocytes, preserved lobular pattern, proper nuclei, and intact visible central vein. Administration with acetaminophen for 14 days showed cellular necrosis, degeneration of nuclei, lipid accumulation, lipid infiltration, portal inflammation, and hepatocyte degeneration (Fig. 3b). Co-administration of AuNPs at different doses minimized the

level of hepatotoxicity (Table 5). Treatment of AuNPs at a dose 175 $\mu\text{g}/\text{kg}/\text{day}$ for 14 days in treated group 4 rats showed highest recovery of cellular architectures (no cellular necrosis, less lipid accumulation, less lipid infiltration, absence of portal inflammations, and no hepatocyte degeneration) in comparison with groups 3, 5, and 6 rats respectively (Fig. 3). The histopathological observations supported the biochemical evidences of hepatoprotection.

Hence, the present study clearly reflected the effectiveness of AuNPs in a dose-dependent manner with maximum hepatoprotection at a dose 175 $\mu\text{g}/\text{kg}/\text{day}$ against acetaminophen-induced hepatotoxicity in experimental rats.

4 Conclusion

To conclude, the results suggest that the green synthesized herbal gold nanoparticles (AuNPs) using an aqueous bark extract of *Terminalia arjuna* at a dose 175 $\mu\text{g}/\text{kg}/\text{day}$ exerted a hepatoprotective effect. Overall, this study demonstrates that AuNPs serve as a novel therapeutic drug which improves the pathophysiological condition associated with liver toxicity. The herbal compounds present in the bark extract of *Terminalia arjuna* exerted their antioxidant activities, which, in combination with gold nanoparticles, helped to ameliorate acetaminophen-induced hepatotoxicity in an experimental animal model. In the future, further work should be done to study the detailed mechanism for the management of hepatotoxicity by using AuNPs which would be beneficial for the society for harmless protection against hepatic dysfunctions by formulation of herbal nanodrug.

Funding Statement None.

Authors' Contributions MM had contributed in definition of intellectual content, literature search, data acquisition, data analysis, manuscript preparation, and manuscript editing. AB had contributed in manuscript editing. GD had contributed in manuscript editing. DKN had contributed in concept, design, manuscript editing, and statistical analysis. All authors have read and approved the manuscript for submission.

Compliance with Ethical Standards

Conflict of Interest The authors declare that they have no conflict of interest.

Research Involving Humans and Animals Statement Animal Ethics approval was maintained as per the Animal Ethical Committee guidelines of Raja Narendra Lal Khan Women's College (reference number: 14/IAEC (05)/RNLKWC/2019) and was maintained as per Committee for the Purpose of Control and Supervision of Experiments on Animal (CPCSEA), Government of India (registration no.:1905/PO/Re/S/2016/CPCSEA).

Informed Consent None.

References

- Yapar, K., Kart, A., Karapehlivan, M., Atakisi, O., Tunca, R., Erginsoy, S., et al. (2007). Hepatoprotective effect of L-carnitine against acute acetaminophen toxicity in mice. *Experimental and Toxicologic Pathology*, 59, 121–128. <https://doi.org/10.1016/j.etp.2007.02.009>.
- Hinson, J. A. (1980). Biochemical toxicology of acetaminophen. *Rev Biochem Toxicol*, 2, 103–130 <https://ci.nii.ac.jp/naid/10024866256>.
- Virupaksha Gupta, K. L., Pallavi, G., Patgiri, B. J., & Kodlady, N. (2011). Relevance of rasa shastra in 21st century with special reference to lifestyle disorders (LSD). *International Journal of Research Ayurveda Pharmacy*, 2, 1628–1632.
- Kulkarni, S. S. (2013). Bhasma and nanomedicine. *International Journal of Research Pharmacy*, 4, 10–16.
- Paul, S., & Chugh, A. (2011). Assessing the role of Ayurvedic 'Bhasmas' as ethno nanomedicine in the metal based nanomedicine patent regime. *Journal Intellectual Property Rights*, 16, 509–515 <http://nopr.niscair.res.in/handle/123456789/13060>.
- Slitt, A. M. L., Dominick, P. K., Roberts, J. C., & Cohen, S. D. (2005). Effects of ribose cysteine pretreatment on hepatic and renal acetaminophen metabolite formation and glutathione depletion. *Basic & Clinical Pharmacology & Toxicology*, 96, 487–494. https://doi.org/10.1111/j.1742-7843.2005.pto_96613.x.
- Gamel El-din AM, Mostafa AM, Al-Shabanah O, Al Bekairi AM, Nagi MN (2003) Protective effect of Arabic gum against acetaminophen induced hepatotoxicity in mice. *Pharmacological Research* 48:631-635. [https://doi.org/10.1016/S1043-6618\(03\)00226-3](https://doi.org/10.1016/S1043-6618(03)00226-3)
- Presscott, L. (2005). Oral or intravenous N-acetylcysteine for acetaminophen poisoning? *Annals of Emergency Medicine*, 45, 409–413. <https://doi.org/10.1016/j.annemergmed.2004.09.028>.
- Melo, D. A. S., Saciura, V. C., Poloni, J. A. T., Oliveria, C. S. A., Filho, J. C. F. A., Padilha, R. Z., et al. (2006). Evaluation of renal enzyme uria and cellular excretion as a marker of acute nephrotoxicity due to an overdose of acetaminophen in Wistar rats. *Clin Chem Acta*, 373, 88–91. <https://doi.org/10.1016/j.cca.2006.05.006>.
- Liebert, J. J., Matlawska, I., Bylka, W. M., & Marek, M. (2005). Protective effect of *Aquilegia vulgaris* (L) on APAP-induced oxidative stress in rats. *J Ethano pharmacol*, 97, 351–358. <https://doi.org/10.1016/j.jep.2004.11.027>.
- Hu, J. J., Yoo, J. S. H., Lin, M., Wang, E. J., & Yang, C. S. (1996). Protective effects of diallyl disulfide on acetaminophen induced toxicities. *Food and Chemical Toxicology*, 34, 963–969. [https://doi.org/10.1016/S0278-6915\(96\)00057-9](https://doi.org/10.1016/S0278-6915(96)00057-9).
- Montilla, P., Barcos, M., Munoz, M. C., Bujalance, I., Munoz-Castaneda, J. R., & Tunez, I. (2005). Red wine prevents brain oxidative stress and nephropathy in streptozotocin-induced diabetic rats. *Journal of Biochemistry and Molecular Biology*, 38, 539–544.
- Mansour, H. H., Hafez, H. F., & Fahmy, N. M. (2006). Silymarin modulates cisplatin-induced oxidative stress and hepatotoxicity in rats. *Journal of Biochemistry and Molecular Biology*, 39, 656–661. <https://doi.org/10.5483/BMBRep.2006.05.23>.
- Law, K., & Brunt, E. M. (2010). Nonalcoholic fatty liver disease. *Clinics in Liver Disease*, 14, 591–604. <https://doi.org/10.1146/annurev-pathol-121808-102132>.
- Freitas Jr., R. A. (2005). What is nanomedicine. *Nanomedicine: Nanotechnology, Biology and Medicine*, 1, 2. <https://doi.org/10.1016/j.nano.2004.11.003>.
- Kulkarni, N., & Muddapur, U. (2014). Biosynthesis of metal nanoparticles: a review. *J Nanotechnol*, 1–8. <https://doi.org/10.1155/2014/510246>.
- Chatha, S. A. S., Hussain, A. I., & Asad, R. (2014). Bioactive components and antioxidant properties of *Terminalia arjuna* L. extracts. *Journal of Food Processing & Technology*, 5, 1–5. <https://doi.org/10.4172/2157-7110.1000298>.
- Karthikeyan, K., Sarala, B. R., Gauthaman, K., Sathish, K. S., & Niranjali, D. S. (2003). Cardioprotective effect of the alcoholic extract of *Terminalia arjuna* bark in an *in vivo* model of myocardial ischaemic reperfusion injury. *Life Sciences*, 23, 2727–2739. [https://doi.org/10.1016/S0024-3205\(03\)00671-4](https://doi.org/10.1016/S0024-3205(03)00671-4).
- Gupta, R., Singhal, S., Guyle, A., & Sharma, V. N. (2001). Antioxidant and hypo cholesterolaemic effects of *Terminalia arjuna* tree-bark powder. A randomized placebo-controlled trial. *Assoc Physicians of India*, 49, 231–235 <https://europepmc.org/article/med/11225136>.
- Mandal, S., Patra, A., Samanta, A., Mandal, A., & Nandi, D. K. (2013). Analysis of phytochemical profile of *Terminalia arjuna* bark extract with antioxidative and antimicrobial properties. *Asian Pacific Journal of Tropical Biomedicine*, 3, 960–966. [https://doi.org/10.1016/S2221-1691\(13\)60186-0](https://doi.org/10.1016/S2221-1691(13)60186-0).
- Mitra, M., Bandyopadhyay, A., Gouri Prasad, D., & Nandi, D. K. (2019). Protective role of green synthesized gold nanoparticles using *Terminalia arjuna* against acetaminophen induced hematological alterations in male Wistar rats. *J Nanomed Nanotechnol*, 10, 2. <https://doi.org/10.35248/2157-7439.19.10.530>.
- OECD guidelines for the testing of chemicals. (1976). Test guideline number 425. Acute oral toxicity study. Organisation for Economic Co-operation and Development, Paris 2008. *Clin Chem Acta*, 70, 19–42.
- Thefeld W, et al (1994) Deutsche Medizinische Wochenschrift 99: 343.
- Schlebusch H, et al (1974) Deutsche Medizinische Wochenschrift 99:765. DOI: <https://doi.org/10.1055/s-0028-1107840>
- Walter M, Gerard H (1980) Microchemical Journal Materials 15: 231.
- Ohkawa, H., Phishi, N. G., & Yagi, K. (1979). Assay for lipid peroxides in animal tissues by thiobarbituric acid reaction. *Analytical and Bioanalytical Chemistry*, 95, 351–358 351.
- Mestrol, R. F., & McDonald, W. (1986). Oxidative enzymes in tissue homogenates. In R. A. Greenwald (Ed.), *CRC handbook of methods for oxygen radical research* (pp. 291–296). Boca Raton: CRC Press.
- Luck HA. Spectrophotometric method for the estimation of catalase. Methods of enzymatic analysis. In Bergmeyer HW, Section 3.1963.
- Moron, M. S., Depierre, J. W., & Mannervik, B. (1979). Levels of glutathione reductase and glutathione S-transferase activities in rat lung and liver. *Biochimica et Biophysica Acta*, 582(1), 67–68 https://www.researchgate.net/profile/Bengt_Mannervik/publication/281266409_Levels_of_glutathioneStransferase_activities_in_rat_lung_and_liver/links/5cb790d892851c8d22f2d6af/Levels-of-glutathione-Stransferase-activities-in-rat-lung-and-liver.pdf.
- Iranloye, B. O., & Bolarinwa, A. F. (2009). Effect of nicotine administration on weight and histology of some vital visceral organs in female albino rats. *Nigerian Journal of Physiological Sciences*, 24, 7–12. <https://doi.org/10.4314/njps.v24i1.46374>.
- Venkatesan, N., Thiyagarajan, V., Naryanan, S., Arul, A., Raja, S., Vijaya, S. G., et al. (2005). Anti-diarrhoeal potential of *Asparagus racemosus* wild root extracts in laboratory animals. *The Journal of Pharmacy and Pharmacology*, 8, 39–46 [https://sites.ualberta.ca/~csps/JPPS8\(1\)/J.Perianayagam/asparagus.pdf](https://sites.ualberta.ca/~csps/JPPS8(1)/J.Perianayagam/asparagus.pdf).
- Sallie, R., Tredger, J. M., & Willaiam, R. (1999). Drugs and the liver. *Biopharmaceutics and Drug Disposition*, 12, 251–259.
- Rosen, G. M., Singletary, W. V., Rauckman, E. J., & Killenberg, P. G. (1983). Acetaminophen hepatotoxicity. An alternative mechanism. *Biochemical Pharmacology*, 32, 2053–2059. [https://doi.org/10.1016/0006-2952\(83\)90426-4](https://doi.org/10.1016/0006-2952(83)90426-4).

34. Saeed, N., Khan, M. R., & Shabbir, M. (2012). Antioxidant activity, total phenolic and flavonoid contents of whole plant extracts *Torilis leptophylla* L. *BMC Complementary and Alternative Medicine*, *12*, 221 <https://link.springer.com/article/10.1186/1472-6882-12-221>.
35. Scott, M. D., Lubin, B. H., Zuo, L., & Kuypers, F. A. (1991). Erythrocyte defense against hydrogen peroxide: preeminent importance of catalase. *The Journal of Laboratory and Clinical Medicine*, *118*, 7–16. <https://doi.org/10.5555/uri:pii:002221439190110S>.
36. Prakash, J., Gupta, S. K., Kochupillai, V., Singh, N., Gupta, Y. K., & Joshi, S. (2001). Chemopreventive activity of *Withania somnifera* in experimentally induced fibrosarcoma tumours in Swiss albino mice. *Phytotherapy Research*, *15*, 240–244. <https://doi.org/10.1002/ptr.779>.
37. Dash, D. K., Yeligar, V. C., Nayak, S. S., Ghosh, T., et al. (2007). Evaluation of hepatoprotective and antioxidant activity of *Ichnocarpus frutescens* (Linn.) R.Br. on paracetamol-induced hepatotoxicity in rats. *Tropical Journal of Pharmaceutical Research*, *6*, 755–765. <https://doi.org/10.4314/tjpr.v6i3.14656>.

Publisher's Note Springer Nature remains neutral with regard to jurisdictional claims in published maps and institutional affiliations.